

Early experience with crimped bovine pericardial conduit for arterial reconstruction

C. A. Salles, L. B. Puig, I. S. Casagrande, G. L. Vieira, R. A. Kalil, L. S. S. Souza, and M. A. M. Andrade Jr.

Hospital Felício Rocho and Federal University of Minas Gerais Medical School, Belo Horizonte, M.G., Brazil

Abstract. A bovine pericardial conduit was developed in the laboratory incorporating the principle of crimping used for synthetic vascular prostheses. The pericardium was processed in glutaraldehyde and the tube was crimped by a technique which preserves the integrity of collagen fibres. This vascular substitute presents a non-thrombogenic and non-porous inner surface which does not require preclotting and does not leak. The material is very soft, easy to handle and suture, coapts nicely to suture lines resulting in a hemostatic anastomosis. The crimping design provides longitudinal elasticity and resistance to collapsing, retains its shape with bending and avoids kinking. Crimping provides a circular tube which makes the construction of the anastomosis easier. Experimental studies in dogs demonstrated absence of thromboembolism with the conduit implanted in the abdominal aorta. Fibrin accumulation was not noted in the convexities of the crimps. This conduit was designed for aortic and pulmonary reconstruction and available in different sizes with or without a biological valve. Initial clinical experience included its use in 10 patients with aortic dissections or aortic aneurysms from August 1989 to March 1990. A reconstruction of the abdominal aorta was performed in 2 patients, the descending thoracic aorta in 2, the ascending aorta in 2 and the ascending aorta including the aortic valve and reimplantation of coronary arteries in 4. For the latter 4, composite crimped pericardial tubes containing a porcine bioprosthesis were used. An additional patient with a single ventricle underwent a Fontan type operation also employing a valved crimped pericardial conduit. Two patients died during the early postoperative period; deaths were unrelated to the conduits. This initial clinical trial showed a mean follow-up of 8 months per patient and any late postoperative complication that could be related to this crimped bovine pericardial conduit has not been observed to date. [Eur J Cardio-thorac Surg (1991) 5:273-279]

Key words: Bovine pericardium - Vascular graft - Vascular substitute - Pericardial conduit - Bioprosthesis

Graft interposition to reestablish aortic continuity was first reported in the late 1940s and early 1950s using preserved human arterial grafts [20, 23, 36]. A porous synthetic vascular prosthesis (Vinyon N) was introduced in 1952 [44] and since that time, several materials were investigated in the laboratory. Dacron became the fabric of choice for vascular prostheses and has been widely used for decades [29, 30].

The outflow tract of the right ventricle has been reconstructed since 1965 using autogenous pericardium [37], aortic allograft [38] and a Dacron tube containing a porcine valve [7]. Problems related to procurement, preservation and surgical technique for the aortic allograft and conduit stenosis for Dacron tubes have limited their use [2, 19, 24].

The ascending aorta, including the aortic valve, has been replaced by different techniques using Dacron tubes

and a prosthetic aortic valve, as well as the aortic arch, descending thoracic and abdominal aorta [1, 5, 12, 16, 17, 27, 32]. Repair of an aortic dissection is often complicated by serious bleeding complications resulting primarily from suture line hemorrhage between the Dacron and the friable aortic wall [1, 12, 27, 28, 32].

Glutaraldehyde preserved bovine pericardium has been used in Brazil since 1979 for enlargement of the ascending aorta [8], followed by the use of valved pericardial conduits for total replacement of the ascending aorta [4]. Softness and flexibility of the pericardium facilitate the construction of the anastomosis with a thin and friable aorta, decreasing the bleeding problems when compared to Dacron tubes [4].

In 1987, we decided to develop a bovine pericardial conduit introducing the principle of crimping used for Dacron vascular prostheses. The technique to crimp the pericardium was researched in the laboratory to provide a satisfactory crimped conduit. Subsequently the tubes were subjected to experimental studies in the laboratory

Read at the 4th Annual Meeting of the European Association for Cardio-thoracic Surgery, Naples, September 17-19, 1990

using dogs as animal models and have been described in detail [13]. The distal infra-renal abdominal aorta was replaced by a 5 cm crimped bovine pericardial conduit in six dogs, using standard surgical procedures employed for the abdominal aorta. The crimping design provides a circular tube, making the construction of the anastomosis easier. The softness and flexibility of the pericardium facilitate the suture resulting in a hemostatic suture line. The animals were sacrificed 3 months later and the conduits removed. No signs of thrombus formation or fibrin deposition were observed between the crimps or in the anastomotic sites. The inner surface of the conduits were absolutely clean and thromboembolic phenomena were not observed through exploration of distal arteries.

This experimental model demonstrated that this conduit is very easy to handle and suture, and that its inner crimped surface is not thrombogenic. *In vitro* studies showed structural and functional integrity of the pericardium after the crimping process.

Based on those experimental and clinical studies [4, 8, 13], a clinical investigational trial was established for the use of crimped bovine pericardial conduits for replacement of the thoracic and abdominal aorta, including the use of composite conduits for total replacement of the ascending aorta and to reestablish right ventricular-pulmonary artery continuity, as well as to correct other kinds of complex congenital cardiac lesions [39].

Material and methods

Pericardial conduit processing

Bovine pericardium is obtained from selected animals in an industrial slaughter house supervised by the State Department of Public Health. It is removed by technical personnel and placed in cold phosphate buffered saline solution at pH 7.4 and 4°C. The pericardium is immediately transported to the laboratory where it is rinsed under sterile conditions, cleaned from fat and loose connective tissue and selected by uniformity and thickness. Following these initial steps, the pericardium is fashioned in rectangular sheets with a uniform thickness between 0.4 and 0.5 mm, and wrapped around a special designed cylinder where the crimping process is carried out. Subsequently it is processed with purified glutaraldehyde in a 0.4% phosphate buffered saline solution at pH 7.4 without pressure fixation. The construction of the conduit is completed by using an interrupted double layer suture technique of 4-0 silicone treated braided multifilament polyester, which allows the conduit to be divided without disruption of the suture line.

Samples are obtained to ensure biochemical, structural and functional integrity of the biological tissue. Tests include light microscope examination using several stains to evaluate the integrity of collagen fibres and tissue structure (Fig. 1), enzymatic digestion with pronase and shrinkage temperature to evaluate the tanning process, as well as tests to measure the tensile strength. It was demonstrated that the crimping process did not affect the integrity and tensile strength of the pericardium.

After mounting, the conduits are placed in a 4% formaldehyde solution for sterilization, and serial cultures are obtained to confirm sterility. They are being manufactured for clinical use by an industrial laboratory with cardiovascular bioprosthetic technology. They are provided as valveless tubes (Fig. 2), and also mounted as a composite conduit containing a porcine aortic valve for total replacement of the ascending aorta (Fig. 3) and for right ventricular outflow tract reconstruction (Fig. 4). The crimped bovine pericardial conduits have longitudinal elasticity, maintain their shape with bending and do not kink even if they are curved to 180° (Fig. 5).

Patients

From August 1989 to March 1990, 10 patients with aortic aneurysm or aortic dissection underwent replacement of the aortic lesion using crimped bovine pericardial conduits preserved in glutaraldehyde (group 1). An additional patient with a single ventricle underwent a Fontan type operation also employing this crimped tube (group 2).

From the 10 patients in group 1, 4 were admitted on an emergency basis due to acute aortic dissection type I in 2, acute aortic dissection type III with rupture in 1 and expanding infra-renal abdominal aortic aneurysm in 1 patient. The other 6 were admitted for elective operations, including annuloaortic ectasia resulting from idiopathic and/or cystic medionecrosis in 4, descending thoracic aorta aneurysm in 1 and aneurysm of the infra-renal abdominal aorta in 1 (Table 1). Preoperative diagnoses were confirmed by aortic angiograms in all patients. The mean age was 56.5 years, ranging from 43 to 73 years, and there were 8 men and 2 women in group 1.

The patient with a single ventricle (group 2), a 3-year-old boy, had undergone a previous repair of aortic coarctation and pulmonary artery banding. He was referred for corrective operation after cardiac catheterization and cineangiogram.

Surgical procedures

Table 2 summarizes the surgical procedures performed on the 10 patients in group 1. For patients with annuloaortic ectasia and aortic dissection type I, a midline sternotomy was employed and extracorporeal circulation using either a bubble or a membrane oxygenator was established using hemodilution and systemic hypothermia to 27°C. Myocardial protection was achieved by means of cold potassium cardioplegia (St. Thomas' solution) injected directly into the coronary ostia. Valved crimped bovine pericardial

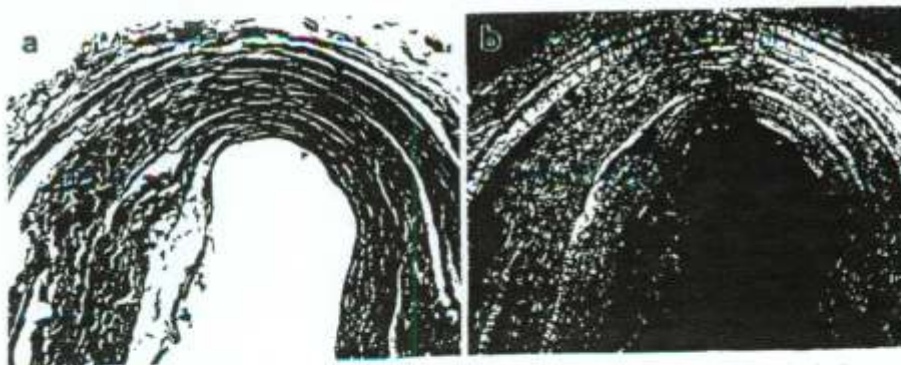


Fig. 1 a, b. Photomicrographs of longitudinal cross-sections of crimped bovine pericardium processed by the glutaraldehyde, showing tissue integrity with preservation of collagen fibres (a $\times 160$, hematoxylin and eosin stain; b $\times 160$, pyro-sirius red stain under polarized light)

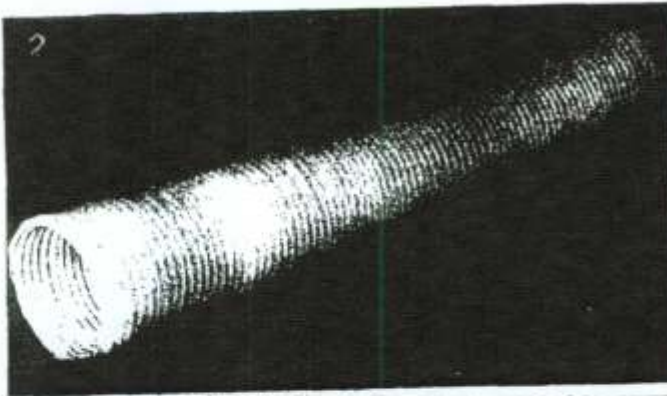


Fig. 2. Crimped valveless bovine pericardial conduit which can be used for the thoracic and abdominal aorta

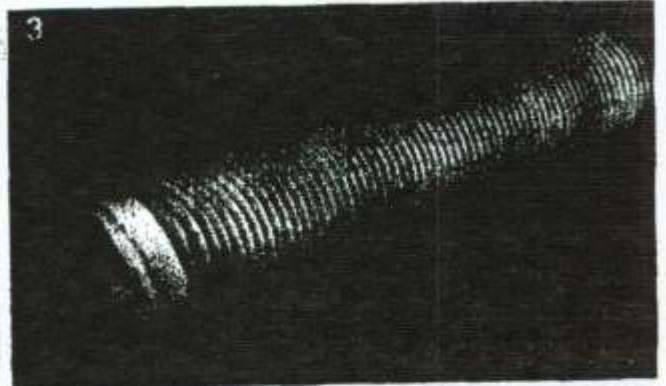


Fig. 3. Crimped bovine pericardial conduit containing a porcine aortic valve for total replacement of the ascending aorta

Fig. 4. Crimped bovine pericardial conduit containing a porcine aortic valve for restoring right ventricular-pulmonary artery continuity and for other kinds of complex cardiac lesions




Fig. 5. The crimped bovine pericardial conduit can flex 180° without kinking

conduits were used for total replacement of the ascending aorta and aortic valve with reimplantation of the coronary arteries, using the technique originally described by Bental and De Bono [5]. Valveless conduits were employed for the 2 patients with aortic dissection type I, preserving the aortic valve. The false lumen was obliterated both proximally and distally using a biological glue (gelatin-resorcin glue polymerized by formaldehyde) and by interrupted mattress sutures reinforced with bovine pericardial strips from both sides of the aorta. A cerclage of the distal aortic anastomosis was accomplished using a strip of bovine pericardium.

A left posterolateral thoracotomy incision through the 4th intercostal space was used for the 2 patients with lesions involving the descending thoracic aorta. The patient with a ruptured aortic dissection required an additional incision through the 7th intercostal space in order to approach the distal thoracic aorta. A midline laparotomy was employed for the 2 patients with infra-renal abdominal aortic aneurysms. For the descending thoracic and abdominal aorta, the procedures were performed with single aortic cross-clamping, using systemic heparinization.

After releasing the aortic cross-clamp, the anastomoses were always carefully inspected for bleeding sites and additional stitches used when necessary. Subsequently, the aneurysmal aorta was wrapped around the crimped pericardial conduit. The aortic anas-

Table 1. Preoperative diagnosis for patients in group 1

Diagnosis	Number of patients
Annuloaortic ectasia	4
Aortic dissection type I	2
Aortic dissection type III	1
Aneurysm of descending thoracic aorta	1
Aneurysm of abdominal aorta	2
Total	10

Table 2. Surgical procedures performed on patients in group 1

Surgical procedure	Number of patients
Bental and De Bono operation	4
Replacement of ascending aorta	2
Replacement of descending thoracic aorta	2
Replacement of infra-renal abdominal aorta	2
Total	10

tomoses were performed using a 4-0 polypropylene suture. Intraoperative bleeding was not a serious problem in any case.

The patient with a single ventricle (group 2) underwent insertion of an intra-atrial baffle to exclude the tricuspid valve from the right atrium and placement of a crimped bovine pericardial conduit containing a porcine aortic valve from the right atrium to the main pulmonary artery under total cardiopulmonary bypass. The crimped conduit accommodated well into the mediastinum.

Results

Two patients died during the early postoperative period in group 1 (20% hospital mortality). Both had been operated upon as emergencies due to acute aortic dissection type I and acute aortic dissection type III with rupture into the extrapleural space. They had early recurrence of aortic dissection through new dissecting sites involving the entire aorta including the vessels from the transverse aortic arch and visceral arteries, which were unable to be corrected.

Three patients presented early postoperative complications. Two developed lung atelectasis followed by respiratory infection, resulting in extended hospitalization. A 73-year-old man with an expanding abdominal aortic aneurysm developed acute renal failure immediately after the operation and as well as acute pancreatitis. In spite of these complications, all 8 survivors recovered completely and were discharged from hospital in a satisfactory clinical condition. The patient with a single ventricle had an uneventful postoperative recovery with significant improvement of his cardiovascular performance.

Late postoperative results

The 9 survivors of the operation were re-examined in August 1990 for a complete follow-up. This initial clinical study showed a mean follow-up of 8 months per patient. The 3-year-old boy had the longest follow-up of 12 months. He is doing very well and is free of symptoms after undergoing a Fontan operation. The echo Doppler study demonstrated a very satisfactory surgical correction with a minimal residual shunt through the intra-atrial baffle.

The 73-year-old man who developed acute renal failure immediately after the operation and had recovered his renal function developed progressive chronic renal failure and required hemodialysis. No other patient in this series presented late postoperative complications and none had problems that could be related to the crimped bovine pericardial conduit.

Discussion

The use of a graft to reestablish aortic continuity was initially reported by Gross in 1949 for the treatment of aortic coarctation using a freeze dried human arterial graft [23]. In 1951, Oudot [36] replaced the aortic bifurcation and Dubost [20] reconstructed the distal abdominal aorta after resection of an abdominal aortic aneurysm in 1952. Both also used preserved human arterial grafts. After a promising initial clinical experience, it became apparent that this non-viable freeze dried conduit underwent aneurysmal dilatation and/or thrombosis [29].

A porous synthetic vascular prosthesis (Vinyon N) was developed in the laboratory by Voorhees, Jaretzki and Blakemore [44] in 1952 and after successful experimental studies in dogs, it was introduced into clinical use [6]. Several other fabric materials were used experimen-

tally and clinically during the years 1950, such as Orlon, Nylon, Ivalon, Teflon and Dacron. The introduction of the principle of crimping allows the conduits to retain their shape with bending and provides longitudinal elasticity. Dacron became the fabric of choice for manufacturing of vascular prostheses which were considered very suitable substitutes for the aorta and iliac arteries. They became commercially available and provided seamless woven, knitted and velour configurations [29, 30]. During the next decades, Dacron tubes were widely used to correct a great variety of aortic lesions, including composite vascular prosthesis containing a prosthetic aortic valve for total replacement of the ascending aorta, as well as other specially designed vascular prostheses [1, 5, 12, 16, 17, 27, 32].

In 1965, Rastelli reported the use of a valveless autogenous pericardium conduit to reestablish continuity between the right ventricle and pulmonary artery to correct pulmonary atresia [37]. A similar procedure was reported by Ross and Sommerville in 1966, using an aortic allograft, including the aorta and aortic valve [38]. Following Ross' report, frozen irradiated aortic allografts were used to correct pulmonary atresia, truncus arteriosus, transposition of the great arteries, and other complex cardiac lesions [31]. However, the incidence of early calcification and obstruction was high [33].

Good long-term results and a low incidence of late calcification have been reported with fresh antibiotic-sterilized aortic valved allografts for reconstruction of the right ventricular outflow tract [21, 25, 26, 40, 43]. Problems related to procurement, availability, preservation and technical details during the operation, including the need to increase the length of the conduit with a Dacron tube have limited its use [19, 24].

In 1973, woven Dacron conduits containing a glutaraldehyde preserved porcine aortic valve were introduced into clinical use for restoring pulmonary artery right-ventricular continuity [7]. They were manufactured in different sizes and models and widely used to correct a great variety of cardiac lesions [9, 10, 14, 22, 35]. However, long-term follow-up demonstrated conduit stenosis, particularly due to formation of a thick fibrous peel and thrombosis between the peel and the fabric [2]. Knitted Dacron double-velour collagen-coated vascular prostheses have been introduced to avoid the complications reported with woven Dacron [42]. Despite this, conduit obstruction was reported due to scar retraction and plication of the conduit by fibrous tissue replacing the absorbable collagen [3].

An autogenous pericardium valved conduit constructed at the time of operation was reported by Schlichter and Kreutzer in 1985 with good initial results in six patients [41].

Bovine pericardium has been widely used for correction of congenital cardiac defects [18]. Although few complications have been observed with its use as an atrial baffle [11, 15], shrinkage, fibrosis and calcification have not been reported when it is used in the right ventricular outflow tract.

Glutaraldehyde preserved bovine pericardium has been used in Brazil by Braile since 1979 for enlargement

of the ascending aorta [8]. Valved bovine pericardial conduits were introduced for total replacement of the ascending aorta, including the aortic valve [4], and for right ventricular outflow tract reconstruction [34], without reported complications to date. Softness and flexibility of the biological tissue were mentioned to facilitate the construction of a hemostatic anastomosis with a diseased aorta. Bleeding complications decreased when compared to Dacron conduits [4], which very often require additional surgical maneuvers to control life-threatening hemorrhage [12, 28]. The aortic wall in the presence of an aortic aneurysm and especially aortic dissection, is very thin and friable and may be calcified. The anastomosis between a thick woven Dacron tube and a diseased weak aorta may be difficult resulting in suture line hemorrhage, which is sometimes uncontrollable and can be fatal [1, 5, 12, 27, 28, 32]. This led to the development of a sutureless intraluminal aortic vascular prosthesis for selected types of acute aortic dissections [1].

In the original report of the technique for replacement of the ascending aorta and aortic valve, Bentall and De Bono [5] wrapped the aneurysmal aorta around the Dacron tube to promote hemostasis from suture lines and interstitial bleeding through the fabric conduit. Cabrol created a fistula between the periprosthetic space and the right atrium after wrapping the aneurysmal aorta around the Dacron tube [12]. Although these procedures can be sometimes necessary to promote hemostasis in the presence of uncontrollable hemorrhage, they can mask important sites of bleeding resulting in late complications, including pseudoaneurysms as recently discussed by Kouchoukos [28]. Other procedures employed to minimize bleeding problems include the use of low porosity woven tubes, different techniques for preclotting and pre-cooking, collagen-coated prostheses and cerclage of the distal anastomosis. An important advance in the treatment of aortic dissection was the introduction of the biological glue (gelatin-resorcin glue polymerized by formaldehyde), which has made a significant change in the prevention and control of intraoperative bleeding [12].

The crimped bovine pericardial conduit is easy to handle during the operation. The crimping design makes a circular tube and maintains its shape during the procedure which facilitates construction of the anastomosis. The pericardium is very soft and coapts nicely to suture lines resulting in a hemostatic anastomosis even when it is anastomosed to a thin and friable aorta. This is particularly useful for reimplantation of the coronary arteries during total replacement of the ascending aorta. Another advantage is that this pericardial conduit has a non-thrombogenic surface, is impermeable, does not require preclotting and does not leak. Intraoperative bleeding with significant blood loss did not occur in any patient in this series. None required reoperation for hemorrhage. When the crimped conduit was placed on the right heart, it was also observed that it can be well positioned and well accommodated in the mediastinum.

This initial follow-up is not long enough to evaluate the crimped bovine pericardial conduit for long-term results such as durability, fibrocalcific degeneration, shrinkage and aneurysmal dilatation. However, the clinical

experience using a pericardial patch for enlargement of the ascending aorta and non-crimped pericardial conduit for total replacement of the ascending aorta has demonstrated good long-term results, up to 10 years, with no report of these complications to date [4, 8]. The reconstruction of the right ventricular outflow tract with a non-crimped bovine pericardial tube has also given good clinical results, without reported complications during a 4-year follow-up [34]. We believe that similar results can be anticipated using crimped bovine pericardial conduits, since the crimping process, as demonstrated by *in vitro* studies, did not affect the structural and functional characteristics of the bovine pericardium.

Acknowledgements. The author is grateful to Dr. Arquimedes N.C. Santos, Dr. Geraldo T. Botrel, Dr. Roberto J.A. Freire, Dr. Fernando E. Almeida Fo and Dr. Paulo E.T. Borém for their valuable technical contributions, and to Dr. Moisés Chuster for his continuing scientific advice. The microscopic sections were kindly performed and interpreted by Dr. Eduardo A. Bambilra.

References

1. Ablaza SGG, Ghosh SC, Grana VP (1978) Use of a ringed intraluminal graft in the surgical treatment of dissecting aneurysms of the thoracic aorta. *J Thorac Cardiovasc Surg* 76: 390-396
2. Agarwal KC, Edwards WD, Feldt RH, Danielson GK, Puga FJ, McGoon DC (1981) Clinicopathological correlates of obstructed right-sided porcine-valved extracardiac conduits. *J Thorac Cardiovasc Surg* 81: 591-601
3. Angelini GD, Witsenburg M, Ten Kate FJW, Hiddema PAE, Quaegebeur JM (1989) Severe stenotic scar contracture of the Microvel Hemashield right-sided extracardiac conduit. *Ann Thorac Surg* 48: 714-716
4. Ardito RV, Santos JLV, Mayorquim RC, Greco OT, Zaiant-Chic M, Soto HG, Jacob JLB, Braile DM (1987) Substituição completa da aorta ascendente e da valva aortica com tubo valvulado de pericardio bovino. *Rev Bras Cir Cardiovasc* 2: 129-138
5. Bentall H, De Bono A (1968) A technique for complete replacement of the ascending aorta. *Thorax* 23: 338-339
6. Blakemore AH, Voorhees AB (1954) The use of tubes constructed from Vinyon "N" cloth in bridging arterial defects: experimental and clinical. *Ann Surg* 140: 324-334
7. Bowman FO Jr, Hancock WD, Malm JR (1973) A valve containing Dacron prosthesis. Its use in restoring pulmonary artery-right ventricular continuity. *Arch Surg* 107: 724-728
8. Braile DM, Ardito RV, Greco OT (1983) Alargamento da raiz da aorta com "patch" de pericardio bovino preservado pelo glutaraldeido. *Arq Bras Cardiol* 41: 289-296
9. Brown JW, Salles CA, Kirsh MM (1977) Extraanatomical bypass of the aortic root: an experimental technique. *Ann Thorac Surg* 24: 433-438
10. Brown JW, Girod DA, Hurwitz RA, Caldwell RA, Rocchini AP, Behrendt DM, Kirsh MM (1984) Apicoaortic valved conduits for complex left ventricular outflow obstruction: technical considerations and current status. *Ann Thorac Surg* 38: 162-168
11. Bullaboy CA (1989) Bovine pericardium: another cautionary note. *Ann Thorac Surg* 48: 743
12. Cabrol C, Pavie A, Mesnilidrey P, Gandjbakhch I, Laughlin L, Bors V, Corcos T (1986) Long-term results with total replacement of the ascending aorta and reimplantation of the coronary arteries. *J Thorac Cardiovasc Surg* 91: 17-25
13. Casagrande ISJ, Puig LB, Salles CA, Ricardo OP (1988) Tubo de pericardio bovino corrugado recoberto com Dacron: novo

- modelo de protese vascular (abstract). *Rev Col Bras Cir* (suppl) 15:153
14. Ciaravella JM Jr, McGoon DC, Danielson GK, Wallace RB, Mair DD, Ilstrup DM (1979) Experience with the extracardiac conduit. *J Thorac Cardiovasc Surg* 78:920-930
 15. Cochran RP, McGouch EC (1987) Bovine pericardium: a source of pulmonary venous obstruction in the Mustard procedure. *Ann Thorac Surg* 44:552-553
 16. Crawford ES, Crawford JL (1984) Diseases of the aorta including an atlas of angiographic pathology and surgical technique. Williams & Wilkins, Baltimore
 17. Crawford ES, Svenson LG, Coselli LS, Safi HJ, Hess KR (1989) Surgical treatment of aneurysm and/or dissection of the ascending aorta, transverse aortic arch, and ascending aorta and transverse aortic arch. *J Thorac Cardiovasc Surg* 98:659-674
 18. Crawford FA Jr, Sade RM, Spinale F (1986) Bovine pericardium for correction of congenital heart defects. *Ann Thorac Surg* 41:602-605
 19. Danielson GK (1985) Discussion of Kay PH, Ross DN [25]. *Ann Thorac Surg* 40:363-364
 20. Dubost C, Allary M, Oeconomos N (1952) Resection of an aneurysm of the abdominal aorta: reestablishment of the continuity by a preserved human arterial graft with result after five months. *Arch Surg* 64:405-408
 21. Fontan F, Choussat A, Deville C, Doutremepuich C, Coupiland J, Vosa C (1984) Aortic valve homografts in the surgical treatment of complex cardiac malformations. *J Thorac Cardiovasc Surg* 87:649-657
 22. Gago O, Salles CA, Stern AM, Spooner E, Brandt RL, Morris JD (1976) A different approach for the total correction of tricuspid atresia. *J Thorac Cardiovasc Surg* 72:209-214
 23. Gross RE, Bill AH Jr, Peirce EC (1949) Methods for preservation and transplantation of arterial grafts: observations on arterial grafts in dogs. Report of transplantation of preserved arterial grafts in nine human cases. *Surg Gynecol Obstet* 88:689-701
 24. Hoots AV, Watson DC Jr (1989) Construction of an aortic homograft conduit for right ventricle to pulmonary artery continuity. *Ann Thorac Surg* 48:731-732
 25. Kay PH, Ross DN (1985) Fifteen years experience with the aortic homograft: the conduit of choice for right ventricular outflow tract reconstruction. *Ann Thorac Surg* 40:360-364
 26. Kirklin JW, Blackstone EH, Maehara T, Pacifico AD, Kirklin JR, Pollock S, Stewart RW (1987) Intermediate-term fate of cryopreserved allograft and xenograft valved conduits. *Ann Thorac Surg* 44:598-606
 27. Kouchoukos NT, Marshall WG, Wedige-Stecher TA (1986) Eleven year experience with composite graft replacement of the ascending aorta and aortic valve. *J Thorac Cardiovasc Surg* 92:691-705
 28. Kouchoukos NT (1989) Aortic graft valve (composite) replacement at 20 years: wrap or no wrap? shunt or no shunt? *Ann Thorac Surg* 48:615-616
 29. Lindenauer SM, Weber TR, Miller TA, Ramsburg SR, Salles CA, Kahn SP, Wojtalik RS (1976) The use of velour as a vascular prosthesis. *Biomed Eng* 11:301-306
 30. Lindenauer SM (1989) The fabric vascular prosthesis. In: Rutherford RB (ed) *Vascular Surgery*, Vol 1, 3rd edn. Saunders, Philadelphia, pp 450-460
 31. McGoon DC, Wallace RB, Danielson GK (1972) Homografts in reconstruction of congenital cardiac anomalies. *Mayo Clin Proc* 47:101-104
 32. Miller DC, Stinson EB, Oyer PE, Moreno-Cabral RJ, Reitz BA, Rossiter SJ, Shumway NE (1980) Concomitant resection of ascending aortic aneurysm and replacement of the aortic valve. *J Thorac Cardiovasc Surg* 79:388-401
 33. Moodie DS, Mair DD, Fulton RE, Wallace RB, Danielson GK, McGoon DC (1976) Aortic homograft obstruction. *J Thorac Cardiovasc Surg* 72:553-561
 34. Moraes CR, Rodrigues JV, Gomes CA, Marinucci L, Santos CL, Coelho TC, Cavalcanti IL (1988) Operação de Rastelli utilizando-se conduto valvulado de pericardio bovino: experiencia inicial. *Rev Bras Cir Cardiovasc* 3:84-92
 35. Norwood WJ, Freed MD, Rocchini AP, Bernhard WF, Castañeda AR (1977) Experience with valved conduits for repair of congenital cardiac lesions. *Ann Thorac Surg* 24:223-232
 36. Oudot J (1951) La greffe vasculaire dans les thromboses du carrefour aortic. *Presse Med* 59:234-236
 37. Rastelli GC, Ongley PA, Davis GD, Kirklin JW (1965) Surgical repair for pulmonary valve atresia with coronary-pulmonary artery fistula: report of a case. *Mayo Clin Proc* 40:521-527
 38. Ross DN, Somerville J (1966) Correction of pulmonary atresia with a homograft aortic valve. *Lancet* II:1446-1447
 39. Salles CA. Discussion of Oliveira HA et al. Uso de protese intraluminal de Dacron para correção de dissecções agudas da aorta. *Rev Bras Cir Cardiovasc* (in press)
 40. Saravalli OA, Somerville J, Jefferson KE (1981) Calcification of aortic homografts used for reconstruction of the right ventricular outflow tract. *J Thorac Cardiovasc Surg* 80:909-920
 41. Schlichter AJ, Kreutzer GO (1985) Autologous pericardial valved conduit. *Rev Lat Cardiol Cir Cardiovasc Infan* 1:43-48
 42. Scott SM, Goddy LR, Sahmel R, Hoffman H (1987) A collagen coated vascular prosthesis. *J Cardiovasc Surg* 28:498-504
 43. Stark J (1989) Do we really correct congenital heart defects? *J Thorac Cardiovasc Surg* 98:1-14
 44. Voorhees AB Jr, Jaretzki A, Blakemore AH (1952) The use of tubes constructed from Vinyon "N" cloth in bridging arterial defects. *Ann Surg* 135:332-336

Dr. Claudio A. Salles
 Av. Celso Porfirio Machado 620
 Bairro Belvedere
 30330 Belo Horizonte, M.G.
 Brazil

Discussion

Dr. I. Gallo (Santander, Spain). I would like to compliment *Dr. Salles* and his group on their work and thank them for letting me study their manuscript beforehand. In 1975, we started using glutaraldehyde preserved heterologous bovine pericardium as a graft material in several positions of the aortoiliac area in the animal laboratory. Although the microscopical aspect of the grafts at the explantation time on occasion was normal, the histological results showed calcification and degeneration of the pericardium after several weeks.

Graft compliance may play an important role in neointimal hyperplasia, vascular thrombosis and tissue degeneration. In natural tissues, corrugations are due to large collagen bundles lying immediately below the endothelial layers. Natural vascular and valvular tissues have a very considerable degree of elastic anisotropy. That means that tissue compliance in the radial, longitudinal or circumferential direction is arranged according to the function. But in isotropic tissues such as pericardium, the material compliance had no specific directional properties. The stresses in the isotropic tissue show restriction on compliance and could be expected to be disadvantageous to the functional performance of the graft. This was one of the most important reasons why early pericardial valve failure occurred.

I have therefore two questions for *Dr. Salles*. The first is, have you observed a different pattern in compliance with this tubular pericardial prosthesis before and after making these artificial corrugations? Secondly, did you measure the compliance of the explanted grafts in the animal model?

Dr. E. Wolner (Vienna, Austria). First, I want to thank *Dr. Salles* for providing me the manuscript in advance. This paper stresses one of the most important points in surgical research, the search for an ideal conduit for cardiovascular reconstruction. However, the success of these glutaraldehyde-treated bovine pericardium as a vascular prosthesis is strongly influenced by some advantages and disadvantages:

Positive aspects of this bioprosthetic material are (1) the softness of the biological tissue which allows easy surgical handling; (2) the storage in bacteriostatic glutaraldehyde solution may provide long-term protection from graft infection, a crucial complication in vascular surgery and (3) decreased thrombogenicity of aldehyde-treated collagenous tissue. Negative aspects of this bioprosthetic graft are (1) the need of the longitudinal suture line, which may serve as a focus for thromboembolic events; (2) well-known release of toxic glutaraldehyde which may inhibit spontaneous host endothelial cell ingrowth and (3), aldehyde-potentiated tissue degeneration which may lead to accelerated aneurysm formation and rupture.

In order to improve these negative aspects of aldehyde-treated biomaterials, we tried to antagonize free, toxic aldehyde groups by soaking in an amino acid solution. As presented yesterday by a member of my department, this treatment significantly improved the degree of spontaneous endothelial cell ingrowth in substitutes of the arteria carotis in sheep as compared to conventionally fixed pericardium.

Aware of these biomaterial-associated problems, I have two questions to the authors concerning human implantation: (1) Do you have any data, perhaps from animal experiments, about long-term durability of your prosthesis as compared to conventionally treated pericardium? (2) Don't you feel that especially the angles of your crimped conduit - areas of increased shear stress - represent foci for accelerated biodegeneration?

Nevertheless, I congratulate the authors to their excellent and very interesting paper.

Dr. C.A. Salles (Belo Horizonte, Brazil). I would like to thank *Dr. Wolner* and *Dr. Gallo* for their kind remarks. I will initially answer *Dr. Gallo's* questions. We did not observe any difference in compliance between crimped and non-crimped bovine pericardium which were submitted to *in vitro* studies to evaluate their functional characteristics. I think one of the major points to obtain a uniform compliance is to select the pericardium with uniform thickness. On the other hand, the crimped conduits have a longitudinal elasticity which represents an increased longitudinal compliance. However, all vascular prostheses, as we know, lose their compliance after implantation since they become encased in fibrous tissue. In regard to his second question, the conduits removed from animal models 3 months after the implantation were not subjected to measurement of their compliance.

Dr. Wolner mentioned his study on the use of aminoacids to decrease the cytotoxicity of the glutaraldehyde preserved pericardium and asked me two questions about the durability of our vascular conduit. I do not have any evidence to demonstrate that this crimped pericardium has a better long-term durability than conventional pericardium, as well as I do not have any data to support that the crimping process could accelerate the biodegeneration. Unfortunately all xenografts treated by the present techniques of tissue preservation will eventually undergo fibrocalcific degeneration.

Before closing this discussion, I would like to say that I followed the presentation of *Dr. Wolner's* study by his group from Vienna at this meeting yesterday, and the paper presented here this morning by *Dr. Frater* from New York on the use of glycerol for pericardium preservation. Both are very interesting and well presented papers. I agree with most of the investigators involved in the biochemistry of collagen cross-linking that glutaraldehyde is not the ideal agent for preservation of collagen tissue. However, a better agent has not been found to date. I also think that the cytotoxicity of the glutaraldehyde may be a problem in several ways. I have discussed with investigators in that area about the possibility to wash out the glutaraldehyde in the laboratory after the tanning process, removing completely the glutaraldehyde from the biologic tissue and about the possibility of keeping these preserved tissues, including bioprosthetic cardiac valves in non-toxic media. The risk of contamination should be solved.

Finally, I would like to comment on another aspect which could be controversial and should be well investigated. In 1987, I had a long discussion in Los Angeles with *Dr. David T. Cheung*, who is a Ph.D. in collagen biochemistry from the University of Southern California. One of the subjects of our discussion was the role of glycerol as an agent for tissue preservation. He pointed out that glycerol is a dehydrating agent and depending on the concentration used, it can dehydrate collagen matrices (replacing water molecules). Glycerol at low concentration can bind collagen tightly and cause collagen to be insoluble but the mechanism is not well known. However, glycerol does not cross-link proteins similar to the collagen cross-linking resulting from glutaraldehyde treatment. I mentioned our previous experience in Brazil using allogeneous duramater valves preserved in glycerol and pointed out that glycerol should be a good agent for tissue preservation, increasing the stability of collagen tissue. *Dr. Cheung* was concerned about the purity and the age of the glycerol used. Commercially available glycerol usually is not pure, but may contain aldehydes, which may be responsible for collagen cross-linking in duramater valves. Pure glycerol by contrast definitively does not cross-link collagen.